

# Septodont Case Studies

## Authors:



**Dr. Fausto Rodrigo Victorino**  
Professor of Endodontics  
at Unicesumar.  
Director of Endo Loft Institute.  
Doctoral degree in Endodontics -  
FOB/USP.



**Dr. Marcelo Augusto Seron**  
Endodontic Specialist  
at Facop/Endo Loft.  
Master's degree in Endodontics -  
FOA/Unesp.

# Bone repair of extensive periapical lesion after endodontic treatment with BioRoot™ RCS

## Abstract

**Introduction:** The aim of the study is to present a case of significant bone repair after endodontic treatment of a maxillary lateral incisor with asymptomatic apical periodontitis.

**Methods:** The treatment was performed using contemporary techniques of instrumentation and cleaning of the root canal and filling with the bioactive endodontic cement BioRoot™ RCS (Saint Maur Des Fossés, France).

**Discussion:** Calcium silicate cements have several advantages, such as biocompatibility,

bioactivity, and the stimulation of bone formation. The use of this material is therefore very convenient and is indicated in cases of apical periodontitis. In the present case, the obturation was performed using the single cone technique associated with bioactive cement.

**Conclusion:** Endodontic treatment in a single session with obturation using the single cone technique associated with BioRoot™ RCS bioactive endodontic cement promoted extensive bone repair in a short time in a tooth with asymptomatic apical periodontitis.



# Introduction

The goal of endodontic treatment is to seal the root canal system in order to avoid its reinfection and prevent the growth of microorganisms that can survive even after the mechanical chemical preparation. Obturation is an important step, but the anatomical complexity of the root canals can make filling difficult and thus compromise the success of the treatment. This is confirmed by the high incidence of failure in cases with poor fillings (Chugal 2003, Haapasalo 2005). Thus, the importance of using a quality filling material is evident.

Cements based on calcium silicate have been highlighted for their antimicrobial activity, biocompatibility and bioactivity (Zhang 2015). They are composed of calcium silicate, zirconium oxide, calcium phosphate, calcium hydroxide and thickening agents (Al Haddad 2016). Due to their antimicrobial activity, flowability and hermetic sealing qualities, they can be used with the single cone technique (Zhou 2013).

These properties have improved the efficacy of root canal obturation and may allow improved sealing even in complex root canal anatomy, providing a success rate greater than 90% in cases with periapical lesion (Chybowski et al. 2018).

In cases of infected necrotic pulp associated with apical periodontitis, an intraradicular infection is well-established and, therefore, procedures must focus on eliminating as well as preventing the introduction of new microorganisms into the root canal system. The success rate of endodontic treatment will depend on the clinician's effectiveness in achieving these goals (Siqueira 2008).

Thus, the aim of the present study was to present a case of significant bone repair after endodontic treatment of a maxillary lateral incisor with asymptomatic apical periodontitis using BioRoot™ RCS cement and the single cone technique.

# Case report

A female patient, 31 years old, was referred for endodontic treatment of the left maxillary lateral incisor tooth. The radiographic examination showed a single straight root canal and a periapical lesion of approximately 10mm (*Figure 1*). Upon clinical examination, the tooth was asymptomatic in thermal and percussion tests, characteristic of asymptomatic apical periodontitis.

Initially, a coronal access was performed with a 1012 diamond spherical bur. After the electronic detection of the working length, rotary chemical mechanical preparation was performed with the SRF SEQUENCE system (MK Life) up to #35.04 file and irrigation with 2.5% sodium hypochlorite. At the end of root canal instrumentation, a final rinse with 17% EDTA and sodium hypochlorite was applied.

Adjunctive treatment was performed with antimicrobial photodynamic therapy (PDT) using the

Laser DUO low-power laser device (MMO, São Carlos, SP, Brazil) with a 0.005% methylene blue photosensitizer (Botica Ouro Preto, Maringá, PR, Brazil). The PDT protocol was performed by inserting methylene blue 0.005% inside the canal, waiting for three minutes (pre-irradiation period) with agitation for one minute with an ultrasonic insert (Irrisonic – E1, Helse Ultrasonic, Santa Rosa de Viterbo, SP, Brazil).

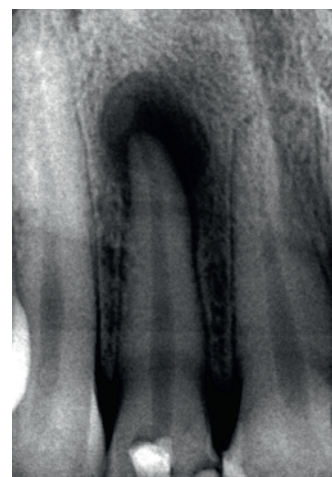
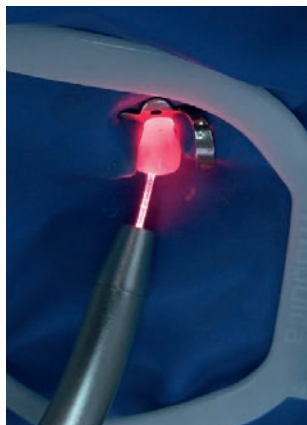
Fig. 01 - Initial X-ray.

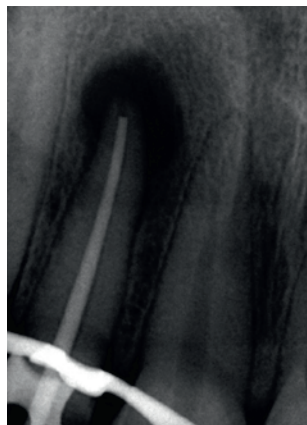
After the pre-irradiation period, the interior of the canal was irradiated for 60 seconds with a laser at the wavelength of red light (660 nm) using an

optical fiber with helical movements 2 mm short of the working length (*Figure 2*).

Finally, the cone test was performed (*Figure 3*) and the root canal was sealed with BioRoot™ RCS

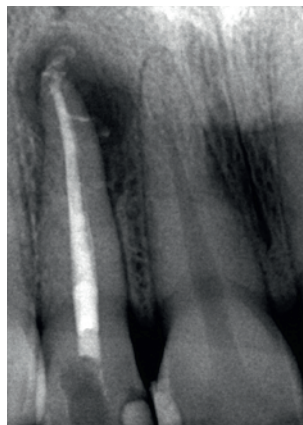


**Fig. 02** - Photodynamic therapy.

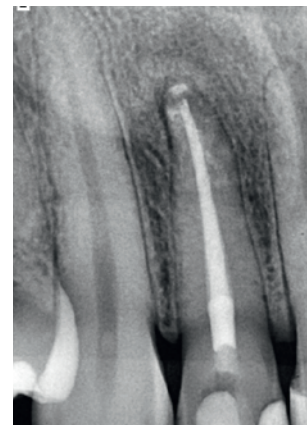

**Fig. 03** - Cone test.

cement with a single cone (*Figure 4*). Coronary sealing was performed with composite resin. At the seven-month radiographic follow-up, practically complete bone repair was observed (*Figure 5*).



**Fig. 04** - Immediate final X-ray.



**Fig. 05** - Seven-month post-operative radiographic image showing complete periapical healing.

## Discussion

After mechanical chemical preparation and consequent significant reduction of microorganisms in the root canal system, the repair of apical periodontitis requires remodeling of the granulomatous tissue and induction of proliferation of bone marrow stem cells and osteoblast precursors into mature osteoblasts, leading to remineralization of the apical tissues. Endodontic cements with the ability to enhance osteogenesis have the potential to promote faster and more predictable repair of apical periodontitis (Giacomino 2019). Calcium silicate-based materials have been widely used in dentistry, and specifically in pulp therapy, due to the excellent biocompatibility and bioactive potential of calcium silicate, which promotes the deposition of hydroxyapatite on the surface (Camilleri 2011; Prati C & Gandolf MG 2015) and favors the survival and differentiation of osteoblasts, cells involved in the formation of mineralized tissue (Giacomino 2019).

BioRoot™ RCS (Septodont, Saint Maur des Fossés, France) is an endodontic cement based on tricalcium silicate with zirconium oxide as a

radiopacifier. Thanks to its outstanding sealing properties and its bioactivity, BioRoot™ RCS allows a tight and lasting seal without the use of complex warm techniques.

When compared to AH Plus, BioRoot™ RCS exhibited a significantly higher percentage of voids through the microtomography analysis, but without significant difference in fluid penetration. That is, both exhibited the same sealing pattern (Viapiana et al. 2016).

The choice of the single cone technique in the present study is due to the fact that this technique is well-described in the literature, with success rates above 85% with follow-ups of four to six years (Chevigny et al. 2008), reaching 90.9% (Chybowski et al. 2018). In addition, it is the most suitable technique for BioRoot™ RCS (Aksel 2021).

Photodynamic therapy has been increasingly used as an aid in endodontic decontamination due to its already demonstrated antimicrobial activity in in vitro (Vendramini et al. 2020) and in vivo (Garcez et

al. 2015) studies. In addition, photodynamic therapy is optimized in the disinfection of endodontic treatments performed in a single session (Rabello et al. 2017). It was evident in the present study that, with a proper decontamination

of the root canal system using different resources, it is possible to perform endodontic treatment in only one session. One of these factors was the use of bioactive BioRoot™ RCS, which stimulated new bone formation in just seven months.

## Conclusion

According to the clinical report presented, it can be concluded that endodontic treatment performed with a single cone technique using BioRoot™ RCS delivered excellent sealing of the root canal

system, promoting extensive bone repair in a short period of time in a tooth with asymptomatic apical periodontitis in a single visit.

## References

- Aksel H, Makowka S, Bosaid F, Guardian MG, Sarkar D, Azim AA. (2021) "Effect of heat application on the physical properties and chemical structure of calcium silicate-based sealers," *Clin Oral Investig.*, May;25(5):2717-2725.
- Al-Haddad A. Che Ab Aziz ZA. (2016) "Bioceramic-based root canal sealers: a review." *Int J Biomater.*, 9753210.
- Camilleri J. (2011) "Characterization and hydration kinetics of tricalcium silicate cement for use as a dental biomaterial," *Dent Mater.*, Aug;27(8):836-44.
- Camilleri J. (2015) "Sealers and warm gutta-percha obturation techniques." *J Endod.*, Jan;41(1):72-8.
- Chugal NM, Clive JM, Spångberg LS. (2003) "Endodontic infection: some biologic and treatment factors associated with outcome," *Oral Surg Oral Med Oral Pathol Oral Radiol Endod.*, Jul;96(1):81-90.
- de Chevigny C, Dao TT, Basrani BR, Marquis V, Farzaneh M, Abitbol S, Friedman S. (2008) "Treatment Outcome in Endodontics: The Toronto Study—Phase 4: Initial Treatment," *Journal of Endodontics*, 34(3):258-263.
- Chybowski EA, Glickman GN, Patel Y, Fleury A, Solomon E, He J. (2018) "Clinical Outcome of Non-Surgical Root Canal Treatment Using a Single-cone Technique with Endosequence Bioceramic Sealer: A Retrospective Analysis," *J Endod.*, Jun;44(6):941-945.
- Enkel B, Dupas C, Armengol V, Apke Adou J, Bosco J, Daculsi G, Jean A, Laboux O, LeGeros RZ. (2008) "Bioactive materials in endodontics," *Expert Rev. Med. Devices*, 5:475–494.
- Garcez AS, Arantes-Neto JG, Sellera DP, Fregnani ER. (2015) "Effects of antimicrobial photodynamic therapy and surgical endodontic treatment on the bacterial load reduction and periapical lesion healing. Three years follow up." *Photodiagnosis Photodyn Ther.*, Dec;12(4):575-80.
- Giacomino C M, Wealleans JA, Kuhn N, Diogenes A. (2019) "Comparative biocompatibility and osteogenic potential of two bioceramic sealers," *J. Endod.*, 45:51–56.
- Haapasalo M, Endal U, Zandi H. (2005) "Eradication of endodontic infection by instrumentation and irrigation solutions," *Endod Topics*, 10:77–102.
- Peters, OA. (2013) "Research that matters—Biocompatibility and cytotoxicity screening," *Int. Endod. J.*, 46:195–197.
- Prati C, Gandolf MG. (2015) "Calcium silicate bioactive cements: Biological perspectives and clinical applications," *Dent. Mater.*, 31:351–370.
- Qureshi A, Soujanya E, Nandakumar P. (2014) "Recent advances in pulp capping materials: An overview," *J. Clin. Diagn Res.*, 8:316–321.
- Rabello DGD, Corazza BJM, Ferreira LL, Santamaria MP, Gomes APM, Martinho FC. (2017) "Does supplemental photodynamic therapy optimize the disinfection of bacteria and endotoxins in one-visit and two-visit root canal therapy? A randomized clinical trial," *Photodiagnosis Photodyn Ther.*, 19:205-211.
- Vallittu PK, Boccaccini AR, Hupa L, Watts DC. (2018) "Bioactive dental materials - Do they exist and what does bioactivity mean?" *Dent. Mater.*, 34:693–694.
- Vendramini Y, Salles A, Portella FF, Brew MC, Steier L, de Figueiredo JAP, Bavaresco CS. (2020) "Antimicrobial effect of photodynamic therapy on intracanal biofilm: A systematic review of in vitro studies," *Photodiagnosis Photodyn Ther.*, Dec;32:102025.
- Viapiana R, Moizadeh AT, Camilleri L, Wesselink PR, Tanomaru Filho M, Camilleri J. (2016) "Porosity and sealing ability of root fillings with gutta-percha and BioRoot™ RCS or AH Plus sealers. Evaluation by three ex vivo methods," *International Endodontic Journal*, 49:774– 782.
- Wang Z. (2015) "Bioceramic materials in endodontics," *Endod Topics*, 32:3–30.
- Weiss P. (2008) "Bioactive materials in endodontics," *Expert Rev. Med. Devices*, 5:475–494.
- Williams DF. (2008) "On the mechanisms of biocompatibility," *Biomaterials*, 29:2941–2953.
- Zhou HM, Shen Y, Zheng W, et al. (2013) "Physical properties of 5 root canal sealers," *J Endod.*, 39:1281–6.

### Septodont

58 rue du Pont de Créteil - 94100 Saint-Maur-des-Fossés - France

[www.septodont.com](http://www.septodont.com)

Follow us on social media channels:

